



# Novel mutations in patients with retinitis pigmentosa detected by Whole Exome Sequencing

Faravareh Khordadpour Deilamania <sup>1\*</sup>

<sup>1</sup> Tehran Medical Genetics laboratory, Tehran, Iran.

\*Corresponding author: Tehran Medical Genetics laboratory, Tehran, Iran. E-mail: [faravarkhordadpoor@yahoo.com](mailto:faravarkhordadpoor@yahoo.com)

Received 2023 January 29; Accepted 2023 February 19.

## Abstract

**Background:** Retinitis pigmentosa is a heterogeneous genetic disorder with progressive degeneration of the retina leading to progressive visual loss.

**Objectives:** This study aimed to identify the probable genetic cause of retinitis pigmentosa in 4 unrelated patients.

**Methods:** Whole exome sequencing was used to investigate the mutations.

**Results:** We found different variants in RP1L1, AIPL1, EYS, and CRB1 genes including three novels and two previously reported mutations.

**Conclusions:** Since the disease has clinical and genetic heterogeneity, whole exome sequencing is the recommended method to find the disease-causing mutations.

**Keywords:** Retinitis pigmentosa, Whole exome sequencing, Vision

## Background

Retinitis pigmentosa is a clinically and genetically heterogeneous group of genetic disorders with progressive degeneration of photoreceptor cells and loss of retinal pigment epithelial function. Rod photoreceptors are degenerated and lead to night blindness and reduction in the visual field. Then the cone photoreceptors degenerate, which results in total vision loss (1). The clinical signs of the disease include waxy disc pallor, pigmentary deposits in the retina, and attenuation of retinal blood vessels. Patients often have severely abnormal or undetectable electroretinography responses since the early stage of the disease. The prevalence of retinitis pigmentosa is almost 1 in 3000–8000 (1–3).

There are two forms of syndromic (such as Bardet-Biedl syndrome and Usher syndrome) and non-syndromic retinitis pigmentosa. It is inherited in an X-linked, autosomal dominant, or autosomal recessive manner. Mutations in different genes that are mostly expressed in photoreceptors or the retinal pigment epithelium cause different clinical phenotypes. Also, different variations in the same gene might cause different disorders (4). Here we report the result of whole-exome sequencing for four RP non-relative patients.

## Methods

After obtaining informed written consent, peripheral blood was taken from the patients. Column-based kits from GeneAll Biotechnology Co., Ltd were used for DNA extraction.


Whole exome sequencing was carried out in BGI Company in Denmark. The capture kit was Agilent SureSelect V7. VCF file was filtered for the genes relevant to the disease. Then databases such as HGMD (academic version), gnomAD, ClinVar, 1000G, ExAC, ESP6500, Kaviar, and Iranome were used to investigate the variants in coding exons and flanking intronic bases. Sanger sequencing was used to confirm the detected variant in patient1.

## Results

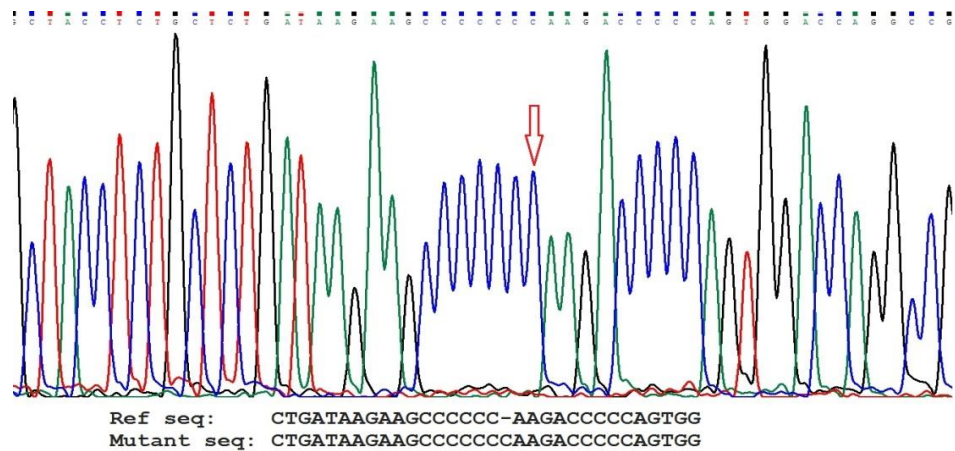
The results are summarized in table 1 and shown in figure 1.

### Patient 1:

Whole exome sequencing revealed a homozygote duplication of one nucleotide in exon 2 of RP1L1 (NM\_178857: c.330dupC: p.K111Qfs\*27) (Figure 1). This mutation was confirmed by Sanger sequencing (Figure 2).



**Figure 1.** IGV software shows the variants detected in four unrelated RP patients using whole exome sequencing. Patient 1: c.330dupC;p.K111Qfs\*27 in RPI1L1 gene, Patient 2: c.C712T;p.Q238X in AIPL1 gene, Patient 3: c.1299+5G>C in EYS gene and Patient 4: c.C2230T;p.R744X and c.T2489A;p.I830N in CRB1 gene.



**Figure 2.** homozygote duplication in RPI1L1 gene in patient 1

**Patient 2:**

In this patient, a novel homozygous nonsense variant c.712C>T:p.Q238X was detected in exon 5 in AIPL1 gene (NM\_014336) (figure 1).

**Patient 3:**

For this patient, we found a novel homozygous splice donor variant c.1299+5G>C in EYS gene (NM\_001142800) (figure 1).

**Patient 4:**

This patient was a compound heterozygote for two variants in CRB1 gene. A nonsense mutation c.C2230T: p.R744X and a missense variant c.T2489A: p.I830N both in exon 7 of CRB1 gene (NM\_201253) (figure 1). (figure 1).

**Table 1.** Whole exome sequencing results in 4 retinitis pigmentosa patients

Patient	Gene	Variant	ACMG Classification	Zygosity	Database	Allele Frequency
Patient 1	RP1L1	chr8:g.10622877dup RP1L1:NM_178857: exon2:c.330dupC:p.K111Qfs*27 (rs770312128)	Pathogenic	Hom	1000G	-
					ExAC	0.000061
					Iranome	0.001250
Patient 2	AIPL1	chr17:g.6426687G>A AIPL1:NM_014336: exon5:c.C712T:p.Q238X	Likely Pathogenic	Hom	1000G	-
					ExAC	-
					Iranome	-
Patient 3	EYS	chr6:g.65384381C>G EYS:NM_001142800.2: c.1299+5G>C	VUS	Hom	1000G	-
					ExAC	-
					Iranome	-
Patient 4	CRB1	chr1:g.197427555C>T CRB1:NM_201253:exon7: c.C2230T:p.R744X (rs150412614)	Pathogenic	Het	1000G	-
					ExAC	0.00002479
					Iranome	-
		chr1:g.197427814T>A CRB1:NM_201253:exon7: c.T2489A:p.I830N	VUS	Het	1000G	-
					ExAC	-
					Iranome	-

*Hom*: Homozygous, *Het*: Heterozygous, *VUS*: Variant of Uncertain Significance

**Discussion:**

Inherited retinal dystrophy has high genetic and clinical heterogeneity. Its genotype-phenotype correlation has been described in some previous studies (5, 6).

Our patients with different severity of RP had variants in different genes. Here we discuss their genotype-phenotype correlation.

In patient 1, who had tunnel vision and mild RP, a homozygote frameshift duplication variant in exon 2 of RP1L1 gene (c.330dupC: p.K111Qfs\*27) was identified by whole exome sequencing, which was confirmed by Sanger sequencing. The patient's parents were relatives, and they had no other affected children but two healthy sons. RP1L1 gene contains four exons, and its first exon is noncoding. Mutations in the RP1L1 gene cause Retinitis pigmentosa-88 (RP88), which is inherited in an autosomal recessive manner. The clinical features of RP88 include night blindness and constriction of peripheral visual fields, with mildly reduced visual acuity, which is consistent with this patient's symptoms (OMIM: 618826). Also, some mutations in this gene cause autosomal dominant occult macular dystrophy (OMIM: 613587)

(7, 8). The detected variant in this gene (rs770312128) is classified as Pathogenic according to ACMG guidelines (9). There have been conflicting interpretations of pathogenicity for this variant in the Clinvar database including one piece of evidence of Likely pathogenic and one piece of evidence of uncertain significance ([www.ncbi.nlm.nih.gov/clinvar/variation/1333246](http://www.ncbi.nlm.nih.gov/clinvar/variation/1333246)). Our report provides more evidence in favor of the pathogenicity of this variant.

Patient 2 has been blind since her birth and was suspected to have Leber congenital amaurosis. Her parents were not relatives and they had no other affected children but 3 healthy daughters and 3 healthy sons. We detected a novel homozygous nonsense variant c.712C>T:p.Q238X in exon 5 in AIPL1 gene on chromosome 17p13. AIPL1 gene has 6 coding exons. Mutations in this gene may cause Leber congenital amaurosis-4 (LCA4), juvenile retinitis pigmentosa, and a form of cone-rod dystrophy. Childhood-onset severe retinal dystrophy is an autosomal recessive heterogeneous group of disorders affecting both rod and cone photoreceptors. The most severe forms are considered Leber congenital amaurosis (LCA), while the milder forms are usually termed juvenile retinitis pigmentosa. Early-onset severe rod-cone dystrophy is an intermediate phenotype (OMIM: 604393) (10, 11). This patient had a severe phenotype of LCA. The detected novel variant in AIPL1 gene causes an amino acid change from Gln to a stop codon at position 238 and is classified as Likely Pathogenic according to ACMG guidelines (9).

Patient 3 had tunnel vision. His parents were first cousins, and they had no other children. He had a novel homozygous splice donor variant (c.1299+5G>C) in EYS gene, which is classified as a Variant of Uncertain Significance (VUS) according to ACMG guidelines (9). Mutations in the EYS gene on chromosome 6q12 cause Retinitis pigmentosa-25 (RP25), which is inherited in an autosomal recessive manner. RP25 is a retinal dystrophy belonging to the group of pigmentary retinopathies. Most patients display night blindness as the initial symptom, constriction of visual fields, retinal bone-spicule pigmentation, attenuated retinal vessels, and a nonrecordable

ERG or ERG responses in a rod-cone pattern (OMIM: 602772) (12, 13).

Patient 4 was diagnosed to have RP in her early childhood, and her vision decreased severely over time. Her parents were distant relatives, and they had one another affected daughter too. This patient had two mutations in CRB1 gene. The first variant (c.C2230T:p.R744X) was a nonsense mutation that causes an amino acid change from Arginine to a stop codon at position 744 and is classified as Pathogenic. The second variant (c.T2489A:p.I830N) was a novel missense, which is classified as VUS.

Mutations in the CRB1 gene on chromosome 1q31 cause Leber congenital amaurosis-8 (LCA8). It includes a group of early-onset childhood retinal dystrophies with the symptoms of profound vision loss, severe retinal dysfunction, nystagmus, photo-dysphoria, keratoconus, high hypermetropia, cataracts, oculodigital sign and a variable appearance to the fundus (OMIM: 613835) (14, 15). Also, retinitis pigmentosa-12 (RP12) is an autosomal recessive severe form of retinitis pigmentosa with age at onset in early childhood, which is caused by mutations in the CRB1 gene (OMIM: 600105). The clinical features include progressive loss of the visual field and severe visual impairment before age twenty (uniprotkb: P82279) (14, 15).

### Conclusion

Due to the genetic and clinical heterogeneity of retinitis pigmentosa latest technologies, such as whole-exome sequencing is the recommended method to find the disease-causing mutations.

### Acknowledgments

I thank the personnel of Tehran Medical Genetics Laboratory for their support. This project was financially supported by Tehran Medical Genetics Laboratory.

### References

1. Ali MU, Rahman MSU, Cao J, Yuan PX. Genetic characterization and disease mechanism of retinitis pigmentosa; current scenario. 3 Biotech. 2017;7(4):1-20.
2. Ullah I, Kabir F, Iqbal M, Gottsch CBS, Naeem MA, Assir MZ, et al. Pathogenic mutations in TULP1 responsible for retinitis pigmentosa identified in consanguineous familial cases. Molecular vision. 2016;22:797.
3. Kabir F, Ullah I, Ali S, Gottsch AD, Naeem MA, Assir MZ, et al. Loss of function mutations in RP1 are responsible for retinitis pigmentosa in consanguineous familial cases. Molecular vision. 2016;22:610.
4. Sun Y, Li W, Li Jk, Wang Zs, Bai Jy, Xu L, et al. Genetic and clinical findings of panel-based targeted exome sequencing in a northeast Chinese cohort with retinitis pigmentosa. Molecular genetics & genomic medicine. 2020;8(4):e1184.
5. Huang X-F, Huang F, Wu K-C, Wu J, Chen J, Pang C-P, et al. Genotype-phenotype correlation and mutation spectrum in a large cohort of patients with inherited retinal dystrophy revealed by next-generation sequencing. Genetics in medicine. 2015;17(4):271-8.
6. Rosenberg T, Schwahn U, Feil S, Berger W. Genotype-phenotype correlation in X-linked retinitis pigmentosa 2 (RP2). Ophthalmic genetics. 1999;20(3):161-72.
7. Noel NC, MacDonald IM. RP1L1 and inherited photoreceptor disease: A review. Survey of Ophthalmology. 2020;65(6):725-39.
8. Zobor D, Zobor G, Hipp S, Baumann B, Weisschuh N, Biskup S, et al. Phenotype variations caused by mutations in the RP1L1 gene in a large mainly German cohort. Investigative Ophthalmology & Visual Science. 2018;59(7):3041-52.
9. Richards S, Aziz N, Bale S, Bick D, Das S, Gastier-Foster J, et al. Standards and guidelines for the interpretation of sequence variants: a joint consensus recommendation of the American College of Medical Genetics and Genomics and the Association for Molecular Pathology. Genetics in medicine. 2015;17(5):405-23.
10. van der Spuy J, Chapple JP, Clark BJ, Luthert PJ, Sethi CS, Cheetham ME. The Leber congenital amaurosis gene product AIPL1 is localized exclusively in rod photoreceptors of the adult human retina. Human molecular genetics. 2002;11(7):823-31.
11. Sacristan-Reviriego A, Le HM, Georgiou M, Meunier I, Bocquet B, Roux A-F, et al. Clinical and functional analyses of AIPL1 variants reveal mechanisms of pathogenicity linked to different forms of retinal degeneration. Scientific reports. 2020;10(1):1-15.
12. Yang L, Fujinami K, Ueno S, Kuniyoshi K, Hayashi T, Kondo M, et al. Genetic spectrum of EYS-associated retinal disease in a large Japanese cohort: identification of disease-associated variants with relatively high allele frequency. Scientific reports. 2020;10(1):5497.
13. McGuigan DB, Heon E, Cideciyan AV, Ratnapriya R, Lu M, Sumaroka A, et al. EYS mutations causing autosomal recessive retinitis pigmentosa: changes of retinal structure and function with disease progression. Genes. 2017;8(7):178.
14. Bujakowska K, Audo I, Mohand-Saïd S, Lancelot ME, Antonio A, Germain A, et al. CRB1 mutations in inherited retinal dystrophies. Human mutation. 2012;33(2):306-15.
15. Beryozkin A, Zelinger L, Bandah-Rozenfeld D, Harel A, Strom TA, Merin S, et al. Mutations in CRB1 are a relatively common cause of autosomal recessive early-onset retinal degeneration in the Israeli and Palestinian populations. Investigative Ophthalmology & Visual Science. 2013;54(3):2068-75.